

4- DD: Swellings Lid

Swellings / Lumps Lid	
1. Localized Lid swellings	
Nodules	Chalazion, Stye, Int Hordeolum, Xanthelesma, Molluscum
Cysts	Cyst of Moll, Cyst of zeiss, Sebaceous cyst
Benign tumours	Viral wart, Seborrhoeic keratosis, Actinic keratosis, Naevi, Capillary hemangioma
Malignant tumours	Basal cell carcinoma, Squamous cell carcinoma, Meibomian cell carcinoma, Malignant melanoma
2. Lid margin swellings	
Blepharitis	Anterior Blepharitis (Infective & non-infective) and Posterior Blepharitis (Meibomianitis)
3. Diffuse Lid swellings	
Allergic	Acute allergic edema, Contact dermatitis
Infectious	Preseptal cellulitis, Herpes simplex, Herpes zoster
In systemic diseases	Renal disease, Congestive cardiac failure, Myoedema

History taking: lid swellings

In history ask about duration of lid swelling and any associated symptoms like pain.

Malignant swellings are usually associated with bleeding, irregular margins and quick increase in size over short span of time.

On examination try to differentiate between localized, lid margin and diffuse lid swelling.

Prof Mahfooz Hussain

Myeyeacademy.com

www.youtube.com/@Profdrmahffozhussain7544




1. Localized lid swellings: Nodules

1. Localized lumps: Lid nodules
Nodule: A growth or semisolid lump wit aggregation of cell

		
Chalazion (Meibomian cyst) Painless & not inflamed	Internal Hordeolum (painful) (infected chalazion)	Stye (Painful) (External Hordeolum)
		
Xanthelasma Usually bilateral	Viral wart Solitary	






1. Localized lid swellings: Cysts

1. Localized lumps: Lid cysts
Nodule: A growth or semisolid lump wit aggregation of cell

	
Cyst of Zeiss Cyst with whitish fluid	Sebaceous cyst Cyst with depressed mouth
	
Cyst of Moll Cyst with clear fluid	





1. Localized lid swellings: Benign tumours

1. Localized lumps: Benign lid tumours

Capillary hemangioma Red swelling	Naevus Br
	
	
Viral wart Irregular mulberry shaped	
	
Seborrhoeic keratosis Dark slightly raised lesion: very common	Actinic keratosis Dark flat lesion: very common

1. Localized lid swellings: Malignant tumours

1. Localized lumps: Malignant lid tumours

	
Basal cell carcinoma (Rodent ulcer) Irregular shaped like ulcer	Squamous cell carcinoma Irregular shaped
	
Sebaceous cell carcinoma At lid margin	Malignant melanoma Pigmented raised lesion

2. Lid margin swellings: Anterior Blepharitis

2. Lid margin swellings: Anterior Blepharitis

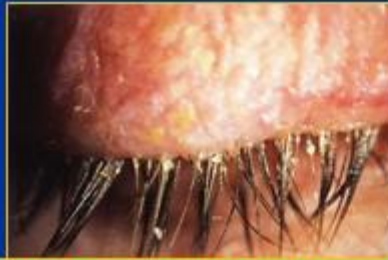Anterior blepharitis affects area surrounding bases of eye lashes

- Infective / Ulcerative anterior blepharitis
- Seborrhoeic / Squamous anterior blepharitis

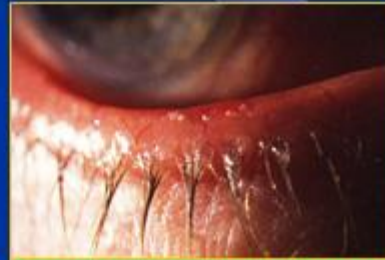Posterior blepharitis meibomian gland. Meibomian gland secretion becomes thick.

- Infective Meibomianitis
- Seborrhoeic Meibomianitis

Seborrhoea means excessive discharge from glands



Infective/Ulcerative Blepharitis
Due to Staphylococcus infection
Scales at lash bases



Seborrhoeic/Squamous Blepharitis
Lashes stuck together with hyperemia and
Telangiectasis of anterior lid margin

2. Lid margin swellings: Posterior Blepharitis

2. Lid margin swellings: Posterior Blepharitis

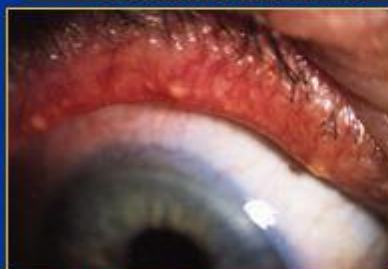Anterior blepharitis affects area surrounding bases of eye lashes

- Infective / Ulcerative anterior blepharitis
- Seborrhoeic / Squamous anterior blepharitis

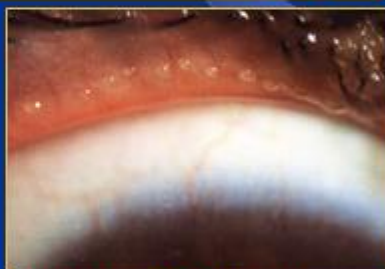Posterior blepharitis meibomian gland. Meibomian gland secretion becomes thick.

- Infective Meibomianitis
- Seborrhoeic Meibomianitis

Seborrhoea means excessive discharge from glands



Infective Meibomianitis
Inflamed and thick lid margins
Toothpaste like meibomian secretions



Seborrhoeic Meibomianitis
Excessive meibomian secretions
With few signs of inflammation
Oily tear film with froth on inner canthus

3. Generalised lid swellings: Allergic

3. Generalized lid swellings: Allergic



Acute allergic edema
Response to any allergan



Contact dermatitis
Usually allergy to topical eye drops

3. Generalised lid swellings: Infections

3. Generalized lid swellings: Infections



Herpes X
Distribution of ophthalmic division of 5th nerve



Herpes simplex
Whitish vesicles



Preseptal cellulitis
Tender firm swelling

3. Generalised lid swellings: Systemic disease

3. Generalized lid swellings: Systemic diseases



Systemic diseases like
Renal disease, Congestive cardiac failure & Myxedema